

Received	2025/09/05	تم استلام الورقة العلمية في
Accepted	2025/09/29	تم قبول الورقة العلمية في
Published	2025/09/30	تم نشر الورقة العلمية في

## Diagnostic Value of Breast Ultrasound Elastography Technique in Evaluation of Breast Masses in Benghazi, Libya

Nadeia Mohammed Elbagermi<sup>1</sup>, Ebtsam Fraj Eljibaly<sup>2</sup>,

Fatma Yousuf Ziuo<sup>3</sup>, Mona Abdelqader Aldirsi<sup>4</sup>

- 1,2. Assistant Professor Radiology Department Faculty of Medicine  
University of Benghazi - Libya
3. Associate Professor Community and Family Medicine Department  
Faculty of Medicine University of Benghazi - Libya
4. Radiology specialist - Radiology Department at Benghazi Medical  
Center, Libya

Correspondent email: fatma.ziuo@uob.edu.ly  
<https://orcid.org/0000-0002-4297-1505>

### Abstract

Breast elastography is a new non-invasive imaging technique used to evaluate the elasticity, or stiffness of breast tissue in addition to conventional breast imaging modalities such as ultrasound (USS) and mammography [1]. The study aimed to assess the clinical value of real-time ultrasound elastography in differentiating malignant from benign breast tumors and To estimate the performance of ultrasound elastography in BIRADS classification of breast lesions. A prospective study was performed in Benghazi Radiology Center El-Hawari and included 80 patients. The USS results of conventional and real-time elastography and histopathology were collected. The data analyzed by and calculation of sensitivity, specificity, positive predictive value (PPV), and negative predictive value NPV, and diagnosis accuracy of B-mode ultrasound and elastography were determined. The informed consent was collected from each participant. The study carried out on 80 patients of different age groups. Their mean age of the studies cases was  $45.9 \pm 17$  years. The current study revealed that the prevalence of malignant breast lesion was high in married women (71%) in older age group  $> 60$  years, while, benign breast lesion represented 83% in single women in younger age group (20-40 years). According to

histopathological classification of our study cases, malignant breast masses was (29%) invasive ductal carcinoma. The investigator reported higher differences in results of sensitivity (96.8%), specificity (97.9%), diagnosis accuracy (97.5%), PPV (96.8%,) and NPP (97.9%) while, that of B-mode ultrasound (93.7%,91.6%,92.5%,88.2%,91.6% respectively). Researchers concluded the elastography is an accurate complementary approach to conventional breast imaging modalities Recommendations: Further research is needed to fully establish elastography's role in clinical practice and optimize its patient benefits

**Keywords:** Breast elastography, BIRADS, positive predictive value (PPV), negative predictive value NPV), diagnosis accuracy.

## القيمة التشخيصية لتقنية الإيلاستوغرافيا بالموجات فوق الصوتية للثدي في تقييم كتل الثدي في بنغازي، ليبيا

نادية محمد البرقومي<sup>1</sup>، ابتسام فرج الجبالي<sup>2</sup>، فاطمة يوسف زيو<sup>3</sup>، منى عبد القادر الدرسي<sup>4</sup>

1و2- أستاذ مساعد، قسم الأشعة، كلية الطب، جامعة بنغازي - ليبيا

3 - أستاذ مشارك، قسم طب المجتمع والأسرة، كلية الطب، جامعة بنغازي - ليبيا

4إخصائي أشعه قسم الأشعة، مركز بنغازي الطبي، ليبيا.

Correspondent email: fatma.ziyo@uob.edu.ly

<https://orcid.org/0000-0002-4297-1505>

### المخلص: تقنية تصوير مر

حديثه غير مخترقه تُستخدم لتقييم مرونة أو صلابة أنسجة الثدي، بالإضافة إلى وسائل والتصوير الشعاعي للثدي (USS) تصوير الثدي التقليدية مثل الموجات فوق الصوتية (الماموغرام) [1]. هدفت هذه الدراسة إلى تقييم القيمة السريرية للتصوير المرن بالموجات فوق الصوتية في الوقت الحقيقي في التمييز بين أورام الثدي الحميدة والخبيثة، وكذلك تقدير أداء التصوير المرن بالموجات فوق الصوتية في تصنيف آفات الثدي وفق نظام BIRADS.

أُجريت دراسة مستقبلية في مركز بنغازي للأشعة - الهواري، وشملت 80 مريضة. تم جمع نتائج الموجات فوق الصوتية التقليدية والتصوير المرن في الوقت الحقيقي، إضافة إلى نتائج الفحص النسيجي للمرضي. جرى تحليل البيانات مع حساب الحساسية، النوعية،

القيمة التنبؤية الإيجابية (PPV) ، القيمة التنبؤية السلبية (NPV) ، ودقة التشخيص لكل من التصوير بالموجات فوق الصوتية بنمط B-mode والتصوير المرئي. تم الحصول على الموافقة المستتيرة من كل مشاركة في الدراسة. أجريت الدراسة على 80 مريضة من فئات عمرية مختلفة، وكان متوسط أعمار الحالات المدروسة  $45.9 \pm 17$  سنة. أظهرت نتائج الدراسة الحالية أن معدل انتشار آفات الثدي الخبيثة كان مرتفعاً لدى النساء المتزوجات (71%) في الفئة العمرية الأكبر من 60 سنة، في حين مثلت آفات الثدي الحميدة نسبة 83% لدى النساء غير المتزوجات في الفئة العمرية الأصغر (20-40 سنة). ووفقاً للتصنيف النسيجي لحالات الدراسة، شكّلت أورام الثدي الخبيثة نسبة (29%) من نوع سرطان القنوات الغازي. أفاد الباحث بوجود تفوق واضح في نتائج التصوير المرئي من حيث الحساسية (96.8%)، النوعية (97.9%)، دقة التشخيص (97.5%)، القيمة التنبؤية الإيجابية (96.8%)، والقيمة التنبؤية السلبية (97.9%)، مقارنةً بالموجات فوق الصوتية بنمط B-mode التي بلغت قيمها (93.7%، 91.6%، 92.5%، 88.2%، 91.6%) على التوالي. يُعد التصوير المرئي تقنية تكميلية دقيقة لوسائل تصوير الثدي التقليدية. هناك حاجة إلى مزيد من الأبحاث لتأكيد دور التصوير المرئي بشكل كامل في الممارسة السريرية وتحسين فوائده للمرضى.

**الكلمات المفتاحية:** إيلاستوغرافيا الثدي، تصنيف BIRADS ، القيمة التنبؤية الإيجابية (PPV)، القيمة التنبؤية السلبية (NPV) ، الدقة التشخيصية.

## 1. Introduction:

Breast cancer is the most prevalent cancer diagnosed globally and the primary cause of cancer-related deaths among women each year [1]. Younger women have been found to have a higher prevalence of breast cancer therefore; early detection and accurate diagnosis are essential for successful treatment and better results [2&3]. The diagnostic modalities that have demonstrated the highest sensitivity in breast cancer include mammography and ultrasound. Mammography is done on dense breast tissue, false-negative findings are frequently obtained [4&5]. The elastography has been developed to determine whether a woman has cancer or not without doing a biopsy <sup>(6)</sup>. Ultrasound elastography is a noninvasive technique and does not involve ionizing radiation, making it a safe and painless procedure for patients, and improving the accuracy of clinical diagnosis, and reducing the unnecessary biopsy of BI-RADSIII, IVa breast lesions [7&8]. Early detection and accurate

diagnosis are critical for effective treatment and to improve the outcomes [1&9]. The concept of ultrasound elastography raised by (Ophir et al ,1991) [10]. In 1997, the first clinical study was published showing the potential of elastography in detection and characterization of breast lesion, while the first practical diagnostic equipment was released in 2003[10].

Breast Imaging Reporting and Date System (BI-RADS): [11&12]  
It is a standardized system developed by the American college of radiology (ACR) to categorize and communicate findings from breast imaging, the BIRADS system provides the radiologists basis to classify breast abnormalities. It provides an important tool to increase the specificity and diagnostic accuracy of ultrasonography of breast lesions <sup>(14,15)</sup>. The BI-RADS classification consists of several categories, ranging from 0 - 6, with each category indicating a different level of suspicion for breast abnormalities. the categories include [11&12]:

- 1) BI-RADS 0:( Incomplete Assessment) category indicates that additional imaging or evaluation is needed to determine the presence or nature of abreast abnormality.
- 2) BIRADS 1:( Negative) category indicates that the imaging findings are normal, and there is no evidence of any significant breast abnormalities, routine screening.
- 3) BI-RADS2: (Benign findings) category indicates the presence of findings that are typically associated with benign breast conditions, routine screening.
- 4) BI-RADS3: (Probably Benign) category suggests findings that have a high probability of being benign (< 2% malignancy), interval follow- up is suggested (6 months).
- 5) BI-RADS4: suspicious Abnormality (>2% but <95%) this category indicates findings that have low to moderate to high suspicion for malignancy, biopsy should be considered.
  - a. BIRADS4A: low suspension for malignancy (>2% to< 10%)
  - b. BIRADDS4B: moderate Suspension for malignancy (>10% to <50%)
  - c. BIRADS4C: high suspension for malignancy: (>50 % to <95%)
- 6) BI-RADS5: highly suspicious of malignancy (>95%) this category suggests findings that have a high suspension of a

malignancy, tissue sampling such as biopsy, is usually recommended for definitive diagnosis.

7) BI-RADS 6: known biopsy proven malignancy. Surgical excision when clinically appropriate [11&12]

## 2. Objectives:

- 1) To assess the clinical value of real-time ultrasound elastography in differentiating between benign and malignant breast cancer.
- 2) To demonstrate the performance of ultrasound elastography in BI-RADS classification of breast lesion.

## 3. Materials and methods:

**3.1.Study design:** A case series study performed in Benghazi El-Hawari Radiology Center.

**3.2.Study period:** from 1<sup>st</sup> January to 31<sup>st</sup> December 2018.

**3.3.Study setting:** The study was performed in Benghazi El-hawari Radiology Center on a selected group of referred patients whose are already underwent breast mass evaluation by radiologist based on the established criteria of B-mode ultrasound.

**3.4.Study population:** the number of patients was involved in this study 80 female patients with different age groups.

### Selection criteria:

#### ▪ Inclusion criteria:

Patients presented with clinical finding of solid breast lesions.

#### ▪ Exclusion criteria:

Other breast diseases.

**3.5. Data collection tool:** The patients' personal data and history were collected. The clinical examination was done. The results of conventional and real -time elastography USS and histopathology were collected.

**3.6.Data analysis:** the data analyzed by use of statistical package social survey (SPSS) version 26, was used for statistical analysis. The estimation of sensitivity, specificity, positive productive value (PPN), negative productive value (NPV) and diagnosis accuracy of B-mode ultrasound and elastography were reported.

### 3.7.Procedure:

**Clinical examination:** Patients were clinically examined by inspection and palpation. During examination, the patient is typically positioned in a comfortable and relaxed manner to optimized imaging and ensure accurate results. the patient is usually lying flat on their back on an examination bed (supine position), one arm is typically raised and positioned behind the head on the same side as the breast being examined to spread the breast tissue and provide better access for the ultrasound transducer. Gel is applied to the breast to provide better conduction of ultrasound wave and facilitate smooth movement of the transducer over the skin.

**Breast ultrasound :** conventional B-mode ultrasound which evaluated according to the BIRADS and strain wave ultrasound elastography examined by using superficial probe ,the ultrasound transducer is gently placed on the breast and moved over the skin in a systematic manner, for the inner medial breast scanning was performed with patient in supine position, for outer lateral breast ,the patient was placed in contra- lateral oblique position ,both axilla were evaluated for pathological lymph nodes, the characteristics were analyzed on grey scale sonogram (including shape of lesion ,size, margin, boundary, internal echo, blood supply) .

For elastography, the same depths, focus positions, and gain settings were used as for conventional images, the elastography image can be obtained within the region of interest (ROI) by compressing and retracting at fixed speed by using probe in direction perpendicular to diagnosis area. In the elastogram, the elastic strain of different tissues was shown by different colors (color map) and strain graph for quantitative assessment and results will be evaluated with the final pathological diagnosis of the cases (the histopathology). The breast tissue is compressed by manual longitudinal pressure applied with transducer or by respiratory movement and the resulting in breast tissue deformation measured to determine its elasticity [9].

**Table 1: Distribution of Focal lesion by strain elastography [9].**

	Benign	Malignant
<b>Texture.</b>	Soft	Stiff
<b>Color display</b>	Red or green	Blue
<b>Size of lesion</b>	Under-estimated	Over-estimated

### **Lesion size comparison technique:**

It Measures the size of the lesion on B-mode before and after strain in elastography image, Differences between the size of breast lesions on B-mode and strain images this is called lesion size comparison technique. Parameters used to measure the lesion size are the height and width for both B-mode and strain images. Malignant lesions tend to be larger on strain images than on corresponding B-mode images, potentially because of the surrounding desmoplastic reaction that accompanies of malignancy. Malignancy is considered when ratio is more than or equal to one [11].

### **Color coded maps:**

A real time tissue elasticity imaging is displayed as a color map called an electrogram, strain electrograms provide a qualitative analysis of distribution of strain within a region of interest (ROI), No strain (stiff tissue) is displayed in blue and high strain (soft tissue) is displayed in red, green indicated average strain in the ROI [11].

Color-scale elasticity images are superimposed on corresponding B-mode images, so that easily recognize the relationship between strain distribution and the lesion on B -mode images [12].Electrograms are evaluated using the Tsukuba scoring system by Dr. Ueno Breast elastography images are classified in five categories [12]: **(Figure1)**

**Score 1:** represents an entirely green lesion with the same elasticity throughout the lesion). (Benign)

**Score 2:** strain is seen within most of lesion but some areas show no strain (green and blue mosaic). (Benign)

**Score 3:** corresponds to high the periphery of the lesion (green) whereas the center of the lesion is blue. (probably Benign)

**Score 4:** indicates no strain is measured within the lesion (entire lesion is blue). (Malignant)

**Score 5:** indicates no strain is measured within the lesion nor in surrounding tissues (the entire lesion and the surrounding tissue are blue). (malignant). Simple breast cysts usually demonstrate on color-coded images an aliasing artifact. The elasticity score is a five-point scale used to classify elastography patterns from benign to malignant as follows: score 1 (benign), score 2 (benign), score 3 (probably benign), score 4 (malignant), and score 5 (malignant) [12].: **(Figure1)** .



	Score	Pattern	Elastogram	B-mode	
Benign ↑	1				Entire hypoechoic area is soft
	2				Part of hypoechoic area is hard
	3				Only inside of margin of hypoechoic area is soft
Malignant ↓	4				Entire hypoechoic area is hard
	5				Hypoechoic area and surrounding area are hard
	BGR				In the case of cysts, a specific blue-green-red pattern (BGR sign) is seen

Figure1: Scoring system by Dr. Ueno [12]

### Strain ratio imaging:

Strain ratio elastography compares the strain of a target tissue with a reference tissue, in breast elastography, the strain ratio between a suspicious lesion and the surrounding normal tissue, the strain ratio is calculated by dividing the strain value of the ROI in the target by the strain value of the ROI in reference region, higher strain ratios indicate stiffer tissues. The ratio is semi quantitative measurement that reflects the relative stiffness of the lesion [11]. most of clinical studies on ultrasound elastography combined both conventional ultrasound and elastography and correlated the elasticity score with the sonographic breast imaging reporting and date system (BI-RADS) to increase the accuracy, sensitivity, and specificity and to reduce the number of unnecessary biopsies [11].

### General appearance of lesions in Elastogram:

In elastography, a color map, also known as an elastogram or elastography image, is a visual representation of tissue elasticity or stiffness. It is generated by assigning different levels of tissue deformation or stiffness. In strain elastography, a color map represents the deformation or strain of the tissue under compression. Stiffer tissues are represented by blue color while softer tissues are represented by red color. Elastogram are superimposed on grayscale B-mode ultrasound images, allowing clinicians to visualize the distribution of tissue stiffness'. Its' important to note that color maps



in elastography are qualitative representation of tissue elasticity and should be interpreted in conjunction with other clinical information and imaging findings [11].

**3.8.Ethics:** The informed consent collected from each patient participated included in the study.

**3.9.Limitations:** while breast elastography is a valuable diagnostic tool, it also has some limitations that should be taken into consideration. Some of the main limitations of breast elastography include:

Operator dependence: the accuracy of breast elastography can be affected by the skill and experience of the operator performing the examination.

#### 4. Results:

The present study included 80 patients of different age groups. Their mean age was  $45.9 \pm 16.99$  years the youngest age group was 20 years and the oldest was 89 years as presented in (table 2). The current study revealed that the prevalence of malignant breast lesion was high in married women (71%) in older age group  $> 60$  years as compared to single in younger age group (17%). While, benign breast lesion represented 83% in single women in younger age group (20-40 years). The current study found that the majority of breast mass (93.8%) presented by benign Lump and 6.3% were malignant masses. Lump and Mastalgia found only in benign masses. Moreover, the present study, 93.8% of breast masses were unilateral (whether benign or malignant) Table3 & Figure 2. Figure show that the highest incidence of breast masses occurs in upper outer quadrant (75%) followed by upper inner quadrant (15%) and then (5.0%) lower outer quadrant, (3.8%) lower inner quadrant and 1.2 upper outer and lower outer quadrants (table3). According to lymph nodes involvement: most of breast cancer drains toward axilla from 34 primary breast cancer patients was 13 patients with axillary lymph nodes metastases, in our study 16% was positive lymph node involvement and 84% was negative (table3). According to BIRADS classification, the cases were divided into two groups, group A included (BIRADS 3) are considered benign breast lesion (58%) and group B included (BIRADS 4A, 4B, 4C, 5) are considered malignant breast lesions According to histopathological classification of the current study cases, fibroadenoma most

common benign breast mass was (60%), malignant breast masses was (29%) invasive ductal carcinoma and (5%) invasive lobular carcinoma, (5%) ductal carcinoma in situ, and (1%) medullary breast cancer (table 5,6 & figure 2).

Table 5 demonstrated a highly significant differences between benign and malignant lesions in the breast as reported by Elastography, where, fishers' exact p value = 0.001. The soft lesions represented 45 (93.8 %) were diagnosed as benign by USS as compared to 31 (96.9%) of cases which hard and diagnosed by USS as malignant breast mass. The current study reported a highly significant differences between benign and malignant lesions where, fishers' exact p value = 0.001 according to BIRADS classification. The study revealed that (97.8%) BIRAD3 were benign cases as compared to BIRADS 4A, 4B, 4C, 5 (40.6%, 43.8, 9.4) respectively were malignant (table 6).

**Table 2: Demographic characteristics of participants:**

Demographic characteristics of patients	No.	%
<b>1) Age intervals</b>		
• 20-40	34	42.5
• 41-60	29	36.3
• 61-90	17	21.3
<b>Mean± SD = 45.9 ± 16.99 years (20 -89 years)</b>		
<b>2) Marital status</b>		
• Married	38	47.5
• Not married	42	52.5
<b>Total</b>	<b>80</b>	<b>100</b>

**Table 3: Clinical characteristics of breast cancer patients:**

Clinical characteristics	No.	%
<b>1. Clinical presentation</b>		
○ Lump	75	93.8
○ Lump & Mastalgia	5	6.2
<b>2. Site</b>		
○ Unilateral	75	93.8
○ Bilateral	5	6.2

<b>3. Anatomical site</b>		
○ UOQ	60	75.0
○ UIQ	12	15.0
○ LOQ	4	5.0
○ LIQ	3	3.8
○ UOQ+LOQ	1	1.2
<b>4. Lymph node involvement</b>		
○ Yes	13	16.3
○ No	67	83.7
<b>Total</b>	<b>80</b>	<b>100</b>

UOQ: Upper outer quadrant    UIQ: Upper inner quadrant  
LOQ : Lower outer quadrant    LIQ : Lower inner quadrant  
UOQ+LOQ : Upper outer quadrant Lower outer quadrant

**Table 4: Relationship between demographic characteristics of the women and USS findings**

Demographic characteristics	USS diagnosis		P -value
	Benign No. (%)	Malignant No. (%)	
<b>1. Age intervals</b>			<b>0.001</b>
20-39	30 (88.2)	4 (11.8)	
≥ 40-59	16 (55.2)	13 (44.8)	
≥ 60-90	0 (0.0)	17 (100)	
<b>2. Marital status</b>			<b>0.001</b>
○ Married	11 (28.9)	27 (71.1)	
○ Not married	35 (83.3)	7 (16.7)	
<b>Total</b>	<b>46(57.5)</b>	<b>34(42.5)</b>	<b>80(100)</b>

**Table 5: Radiological and histopathological findings of breast cancer patients**

Radiological	Diagnosis by USS			P -value
	Benign No. (%)	Malignant No. (%)	Total	
<b>Elastography</b>				<b>0.000*</b>
• Soft	45 (93.8)	3 (6.3)	48(60)	
• Hard	1 (3.1)	31 (96.9)	32(40)	

IDC: Invasive ductal carcinoma    ILC: Invasive lobar carcinoma  
DCIS: Ductal carcinoma in situ    MC: Medullary carcinoma

<b>Histopathology</b>				
• Fibroadenoma	44 (91.7%)	4 (11.8)	48(60)	0.000
• IDC	2 (8.7%)	21 (61.8)	23(28.8)	
• ILC	0 (0.0%)	4 (11.8)	4 (5)	
• DCIS	0 (0.0%)	4 (11.8)	4 (5)	
• MC	0 (0.0%)	1 (2.8)	1(1.25)	
<b>Total</b>	<b>46(57.5)</b>	<b>34(42.5)</b>	<b>80(100)</b>	

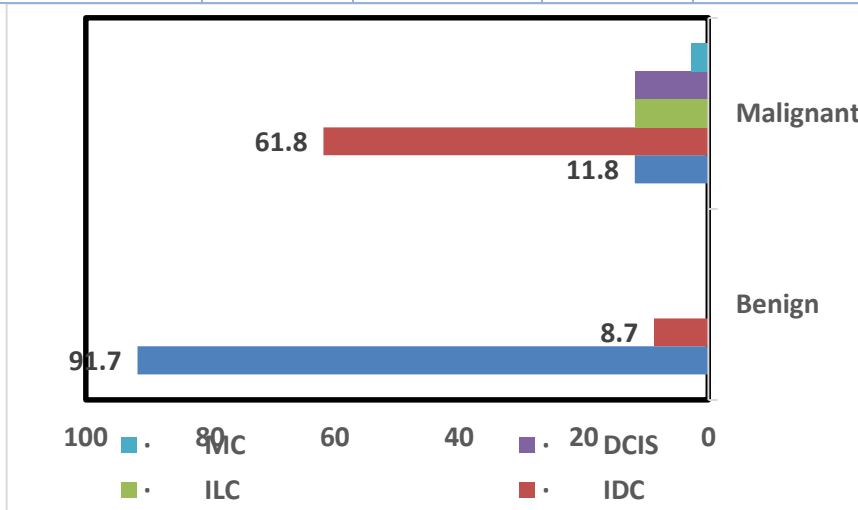


Figure 2: Diagnosis by USS and Histopathology

**Table 6: BIRADS classification of breast cancer**  
**BIRAD: Breast Imaging Reporting and Date System**

BIRADS classification	Elastography		To tal	P -value
	Soft No. (%)	Hard No. (%)		
BIRAD3	45(97.8)	1 (3.1)	46(57.5)	
BIRAD4A	3(75.0)	1 (3.1)	4(5)	
BIRAD4B	0 (0.0)	13(40.6)	13(16.2)	
BIRAD4C	0 (0.0)	14(43.8)	14(17.5)	
BIRAD5	0 (0.0)	3 (9.4)	3(3.8)	0.000
<b>Total</b>	<b>48(60)</b>	<b>32(40)</b>	<b>80(100)</b>	

**Sensitivity and specificity of elastography and ultrasound:**

(1) **Sensitivity:** It is the ability to detect a high proportion of true positives that is to give very few false negative results. In other words, sensitivity represent, Positive cases among diseased or the ability of the screening test to detect true positive among all positive.  
 $=TP/(TP+FN) \times 100\%$ .

(2) **Specificity:** It is the ability to detect or identify the true negatives that is to give very few false positive results. In other words, specificity represent, Negative cases among Health or the ability of the screening test to detect true negative among all negative.

$$=TN/(TN+FP) \times 100\%.$$

(3) **Positive Predictive value:** The predictive value of positive test (No of true positive/total No of positive lesions) %.

$$PPV=TP/(TP+FP) \times 100\%.$$

(4) **Negative predicative value (NPV):** the predictive value of negative test (No. of true negative/total No of negative lesions) %.

$$NPV=TN/(TN+FN) \times 100\%.$$

(5) **Diagnostic accuracy:** (No. of true positive +No. of true negative)/total No. of lesions.

**Table 7: Compared between Elastography and USS in the studied cases:**

Results of the tests	Elastography	USS
○	Number	%
○ TP	31	30
○ FP	1	4
○ FN	1	2
○ TN	47	44
○ Sensitivity	96.8	93.7
○ Specificity	97.9	91.6
○ PPV	96.8	88.2
○ NPV	97.9	91.6
○ Diagnostic accuracy	97.5	92.5

## 5. Discussion:

Elastography is a non-invasive new imaging technique that measures the stiffness or elasticity of breast tissue. Real-time elastography can be a supplementary approach to conventional ultrasound to improve the diagnostic accuracy of malignant breast lesions.

Several studies have investigated the diagnostic accuracy of breast elastography, particularly in comparison to other imaging techniques such as mammography and ultrasound.

The results of current study that the sensitivity of B-mode ultrasound was 93.7% and for Uss elastography was 96.8% while specificity was 91.6% and 97.9% respectively, and diagnostic accuracy was 92.5%,97.5% respectively, PPV was 88.2% for B mode USS and 96.8% for USS elastography, NPV was 91.6% and 97.9% respectively. Italian multicenter clinical trial, real time elastography of 874 breast lesions with definitive diagnosis (614 benign and 260 malignant) showed a very high specificity in benign lesions, including BIRADS 3 lesions, NPV was 98% for all the lesions and 96.3% for all the BIRADS 3 lesions. Barr et al. ,(2006)<sup>(17)</sup> examined the diagnostic performance of strain elastography in differentiating benign and malignant breast lesions. Total sample of 635 breast lesions demonstrated that elastography improved the specificity of ultrasound in breast lesion evaluation.

Thomas et al. (2006) [13] investigated the addition of real-time elastography to conventional B-mode ultrasound (US) and mammography in a cohort of breast lesions and reported that elastography in combination with B-mode US improved differentiation between benign and malignant lesions. According to the abstract, the authors reported a superior specificity and positive predictive value (PPV) for the elastography-augmented assessment compared with B-mode alone [12]. Although your summary gives B-mode US with sensitivity 91.8% and specificity 78%, and elastography observers with sensitivities ~77.6% / 79.6% and specificities ~91.5% / 84.7%, I did *not* locate those exact pairings in the accessible abstract; the published summary simply notes “improved differentiation” rather than the exact numbers you listed. The authors concluded that real-time sono-elastography is a reliable adjunct to B-mode ultrasound for evaluation of breast lesions [13].

S M Tan, Teh H S, Mancner J F, et al. (2008) [14] evaluated 550 breast lesions (119 malignant, 431 benign) and demonstrated that real-time ultrasound elastography improved the performance of B-mode ultrasound. They reported an elastography sensitivity of 78.0 %, specificity of 98.5 %, and overall accuracy of 93.8 %. (19) The authors concluded that elastography was “user-friendly” and could improve the assessment of breast lesions when added to B-mode imaging [14].

S Wojcinski et al. (2010) [15] conducted a multicenter study of real-time tissue elastography in 779 breast lesions (histologically confirmed) and found that when combining the BI-RADS US classification with sonoelastography the specificity improved to 89.5% and PPV to 86.8% compared with B-mode ultrasound alone (specificity 76.1% and PPV 77.2%). They further reported that in dense breast tissue (ACR III–IV) specificity reached 92.8% [14]. They concluded that the adjunctive use of elastography significantly enhances diagnostic performance in breast ultrasound [15]. In the case of Ji Hyun Youk et al. (2009) [16] the study compared strain and shear-wave elastography combined with B-mode ultrasound in differentiating benign from malignant breast lesions. They reported area under the curve (AUC) values of 0.982 for strain elastography, 0.987 for shear-wave elastography, and 0.970 for B-mode alone ( $p < 0.05$ ); when elastography was added, 38% (for SE) and 56% (for SWE) of benign BI-RADS 4a lesions could be downgraded without false negatives [16]. Youk et al. (2009) [16] demonstrated that strain elastography improved the accuracy of ultrasound” — the published paper supports the notion of improved performance when elastography is added.

A Ozsoy et al. (2016) [17] evaluated the diagnostic performance of real-time strain elastography in BI-RADS 4 and 5 breast masses. They reported for strain-ratio assessment a sensitivity of 78.8 %, specificity of 78.3 %, PPV 86.7 % and NPV 67.0 %; for elasticity-score system sensitivity 83.3 %, specificity 74.6 %, PPV 85.7 % and NPV 71.0 %. Their conclusion was that combining strain-ratio and color-scoring evaluation enhanced diagnostic performance [17].

M Georgieva et al. (2019) [18] assessed the diagnostic performance of ultrasound strain elastography for differentiation of malignant lesions in a cohort of 86 patients (36 malignant). They found that



the sensitivity of both strain elastography and conventional B-mode ultrasound was 97 % whereas B-mode alone had a sensitivity of 92 %; the respective specificities were 82 % (elastography + B-mode) and 73 % (B-mode alone). [18] The authors concluded that elastography can act as a supplementary approach to improve diagnostic accuracy of malignant breast lesions [18].

J Li et al. (2021) [19] investigated the diagnostic performance of strain elastography in detecting breast cancer in women with dense breasts. They concluded that elastography improved sensitivity and negative predictive value (NPV) in the setting of dense breast tissue. [19]

### Conclusion and Recommendations:

- Elastography provides complementary information to conventional imaging modalities such as mammography and ultrasound. By assessing tissue stiffness or elasticity, elastography can aid in the diagnosis, characterization, and monitoring of breast lesions.
- Differentiation between benign and malignant lesions based on their elasticity characteristics. Malignant tumors often exhibit increased stiffness, while benign lesions tend to be more elastic. this can assist in determining the need for further diagnostic procedures or interventions.
- Prediction of tumor invasiveness: malignant tumors with increased stiffness are more likely to be invasive and require more aggressive management strategies.
- Monitoring treatment response: Elastography can be used to monitor the response to breast cancer treatment. changes in tissue elasticity over time can indicate the effectiveness of therapy and help guide treatment decisions.
- It was found that conventional B-mode ultrasound examination had a sensitivity of 93.7%, specificity of 91.6% and accuracy of 92.5%, while elastography had sensitivity of 96.8%, specificity of 97.9% and accuracy 97.5% according to these results, Elastography had higher sensitivity, specificity and accuracy than B-mode ultrasound.

- Reduction of unnecessary biopsies, by providing additional information about tissue elasticity, it can help differentiate benign from malignant lesions, potentially avoiding invasive procedures for benign conditions.

**Acknowledgment:** to all patients participate in the study

Conflict of interest – non Funding – no.

## 6. References:

- [1] Łukasiewicz S, Czezelewski M, Forma A, Baj J, Sitarz R, Stanisławek A, et al. Breast cancer epidemiology, risk factors, classification, prognostic markers, and current treatment strategies: an updated review. *Cancers*. 2021;13(17):4287.
- [2] Radecka B, Litwiniuk M. Breast cancer in young women. *Ginekol Pol*. 2016;87(9):659–63.
- [3] Shoemaker ML, White MC, Richardson LC, Edwards BK, Henley SJ. Differences in breast cancer incidence among young women aged 20–49 years by stage and tumor characteristics, age, race, and ethnicity, 2004–2013. *Breast Cancer Res Treat*. 2018;169:595–606.
- [4] Obeagu EI, Obeagu GU. Breast cancer: A review of risk factors and diagnosis. *Medicine*. 2024;103(3):e36905.
- [5] Saarenmaa I, Salminen T, Geiger U, Heikkilä M, Hyvärinen S, Ikonen T, et al. The effect of age and breast density on the sensitivity of breast cancer diagnosis by mammography and ultrasonography. *Breast Cancer Res Treat*. 2001;67:117–23.
- [6] Klimberg VS, Rivere A. Ultrasound image-guided core biopsy of the breast. *Chin Clin Oncol*. 2016;5(3):33.
- [7] Lee SH, Chang JM, Cho N, Koo HR, Yi A, Kim SJ, et al. Practice guideline for the performance of breast ultrasound elastography. *Ultrasonography*. 2014;33(1):3–10.

- [8] Balleyguier C, Canale S, Ben Rejeb M, et al. Breast elastography: the technical process and its applications. *Diagn Interv Imaging*. 2013;94(5):503–13.
- [9] Gennisson JL, Deffieux T, Fink M, Tanter M. Ultrasound elastography: principles and techniques. *Diagn Interv Imaging*. 2013;94(5):487–95.
- [10] Ophir J, Céspedes I, Ponnekanti H, Yazdi Y, Li X. Elastography: a quantitative method for imaging the elasticity of biological tissues. *Ultrason Imaging*. 1991;13(2):111–34.
- [11] Barr RG. The role of sonoelastography in breast lesions. *Semin Ultrasound CT MR*. 2018;39(1):98–105.
- [12] Kim SY, Park JS, Koo HR. Combined use of ultrasound elastography and B-mode sonography for differentiation of benign and malignant circumscribed breast masses. *J Ultrasound Med*. 2015;34(11):1951–9.
- [13] Thomas A, Kümmel S, Fritzsche F, Warm M, Ebert B, Hamm B, Fischer T. Real-time sonoelastography performed in addition to B-mode ultrasound and mammography: improved differentiation of breast lesions? *Acad Radiol*. 2006;13(12):1496-504.
- [14] Tan SM, Teh HS, Mancner JF, Poh WT. Improving B-mode ultrasound evaluation of breast lesions with real-time ultrasound elastography – a clinical approach. *Breast*. 2008;17(3):252-7.
- [15] Wojcinski S, Farrokh A, Weber S, Thomas A, Fischer T, Slowinski T, Schmidt W, Degenhardt F. Multicenter study of ultrasound real-time tissue elastography in 779 cases for the assessment of breast lesions: improved diagnostic performance by combining the BI-RADS-US classification system with sonoelastography. *Ultraschall Med*. 2010 Oct;31(5):484-91.
- [16] Youk JH, Son EJ, Gweon HM, et al. Comparison of strain and shear wave elastography for the differentiation of benign from malignant breast lesions, combined with B-mode

- ultrasonography: qualitative and quantitative assessments. *Ultrasound Med Biol.* 2014 Oct;40(10):2336-44.
- [17] Ozsoy A, Acar D, Barca AN, Aktas H, Araz L, Ozkaraoglu O, Yuksel E. Diagnostic performance of real-time strain sonoelastography in BI-RADS 4 and 5 breast masses. *Diagn Interv Imaging.* 2016 Sep;97(9):883-9. doi: 10.1016/j.diii.2016.04.004. Epub 2016 Jul 7. PMID: 27211021.
- [18] Georgieva M, Prantl L, Utpatel K, Wiesinger I, Stroszczynski C, Jung F, Jung EM. Diagnostic performance of ultrasound strain elastography for differentiation of malignant breast lesions. *Clin Hemorheol Microcirc.* 2019;71(2):237-247. doi: 10.3233/CH-189415. PMID: 30584133.
- [19] Yan J, Fang S. Diagnostic performance of ultrasound elastography in differentiating malignant from benign breast microcalcifications: a case-control study. *BMC Med Imaging.* 2025 Apr 24;25(1):134. doi: 10.1186/s12880-025-01638-9. PMID: 40275172; PMCID: PMC12023353.